


A COMPARATIVE STUDY ON THE FUNCTIONAL OUTCOME OF INTERTROCHANTERIC FRACTURES TREATED BY PROXIMAL FEMORAL NAILING OR DYNAMIC HIP SCREW FIXATION IN ELDERLY

Dr. Abhishek Salgaonkar  , Dr. Ganesh M T  

¹Sree Balaji Dental College and Hospital, Chennai, Tamil Nadu, India

²Assistant Professor, Department of Orthopedics, Sree Balaji Dental College and Hospital, Chennai, Tamil Nadu, India



Received 28 February 2026

Accepted 17 April 2026

Published 04 May 2026

Corresponding Author

Dr. Abhishek Salgaonkar,
absalgaonkar05@gmail.com

DOI

[10.29121/shodhkosh.v7.i7s.2026.7946](https://doi.org/10.29121/shodhkosh.v7.i7s.2026.7946)

Funding: This research received no specific grant from any funding agency in the public, commercial, or not-for-profit sectors.

Copyright: © 2026 The Author(s). This work is licensed under a [Creative Commons Attribution 4.0 International License](https://creativecommons.org/licenses/by/4.0/).

With the license CC-BY, authors retain the copyright, allowing anyone to download, reuse, re-print, modify, distribute, and/or copy their contribution. The work must be properly attributed to its author.



ABSTRACT

Background Hip fracture is common among the elderly, particularly as a result of weak bones and falls. They tend to result in mobility and loss of independence.

Objective: The paper will compare two forms of surgery Proximal Femur Nailing (PFN) and Dynamic Hip Screw (DHS) in order to determine which one produces a better recovery.

Methods: There were 96 patients above 60 years old. They were separated into two categories one of which was treated with PFN and other one was treated with DHS. Harris hip score (HHS) was used to check their hip functioning at 1, 3, and 6 months. The rate at which the bone healed was viewed through x-rays.

Findings: Patients that underwent PFN had improved bone healing and hip motions as compared to those that underwent DHS. PFN had less complications.

Conclusion: PFN is more suitable in case of unstable fractures as it provides more stability and quicker healing whereas DHS is more effective in case of stable fractures.

Keywords: Intertrochanteric Fracture, Old Age, PFN, DHS, Harris Hip Score, Bone Healing

1. INTRODUCTION

The injuries in older adults are very severe, including hip fractures (Lim et al., 2018). Their occurrence is normally as a result of poor bones (osteoporosis) and low falls which would not cause injury in young individuals. Intertrochanteric fractures are the commonest of all the types of hip fracture, occurring in the upper region of the femur, between the greater and lesser trochanter (Mohindra & Jain, 2017). These fractures not only act as a pain and immobility causing trait but also result in health-threatening issues, such as loss of autonomy, prolonged hospitalization, and

expensive healthcare costs. A hip fracture becomes the first symptom of the worsening of physical capabilities and general quality of life in old age.

As life expectancy has increased and as the number of elderly persons continues to grow, the cases of intertrochanteric fracture are on the increase annually (Pignolo et al., 2010). This issue will increase at a fast rate in India and other developing nations due to the poor condition of bones and a lack of knowledge about osteoporosis prevention (Sheng et al., 2023). Majority of the patients cannot walk after the injury and immobility over a considerable period may lead to complications like pressure ulcers, pulmonary infection and deep vein thrombosis. Therefore, early surgical fixation and rehabilitation are considered the standard treatment to help patients regain mobility and prevent these complications.

The main goal of treatment for intertrochanteric fractures is to achieve stable fixation, allow early mobilization, and restore independent walking ability as soon as possible (Canale & Beaty, 2012). Over time, several implants and surgical techniques have been developed for this purpose.

2. THE TWO MOST COMMONLY USED METHODS ARE

- **Dynamic Hip Screw (DHS):** This is an extramedullary implant that consists of a lag screw placed inside the femoral neck and head, connected to a side plate fixed to the shaft (Regazzoni et al., 2012). It allows controlled sliding and compression at the fracture site, which promotes healing. DHS has been the traditional method for decades and gives good results in stable fracture patterns (AO/OTA type A1).
- **Proximal Femoral Nailing (PFN):** This is an intramedullary implant inserted through the tip of the greater trochanter and lies within the bone marrow canal (Browner, 1996). Compared to DHS, it has a shorter lever arm, less flexing stress, and mechanical stability. PFN comes in handy especially in unstable fractures (type A2 and A3) when the fragments of the bone are displaced or comminuted. FNP insertion within the bone results in premature weight-bearing and reduced chances of implant failure.

The options to be made on the type of implant to be used is interdependent on the stability of the fracture, quality of the bone, experience of the surgeon, and availability of equipment. Whereas DHS has less expensive cost and is simpler to apply, PFN offers better fixation and reduced possibility of mechanical breakdown in osteoporotic bone. PFN, however, is more difficult to insert in the operating room and is prone to complications such as screw back-out or the “Z-effect”.

Past literature has given conflicting results. PFN was said to give faster union and earlier mobilization by some of the authors with no significant difference in the functional outcome of the two techniques being compared. The argument is ongoing and there is more comparative research which is required to inform surgeons to make the most optimal choice when dealing with a patient.

This research proposal is aimed at comparing functional and radiological results of intertrochanteric fractures undergoing DHS and PFN in older patients. The Harris Hip Score (HHS) will be used to evaluate the functional outcome at various intervals whereas radiological healing and complication will be evaluated. This is done to determine the implant that will provide better outcomes in mobility, healing period and general recovery to the elderly patients with various fracture patterns.

Figure 1

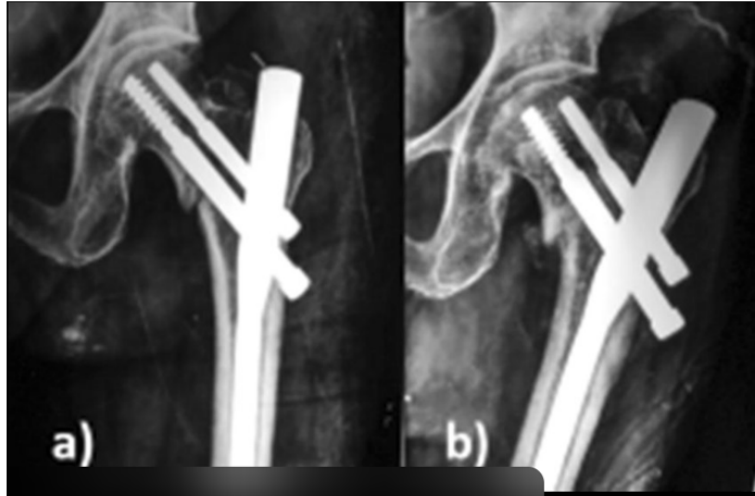

Figure 1 X-ray Showing an Intertrochanteric Fracture of the Femur in an Elderly Patient., Figure 1a: Post-Operative X-ray Showing Fixation with a Dynamic Hip Screw (DHS), Figure 1b: Post-Operative X-ray Showing Fixation with a Proximal Femoral Nail (PFN).

Objectives

- 1) To compare the post surgery hip functioning with the help of Harris hip score.
- 2) To determine what approach contributes to the faster healing of bones.
- 3) To record the issues of the surgery including infection or screw movement.

3. METHODOLOGY

3.1. STUDY DESIGN

This was a prospective comparative study which was done in the Department of Orthopaedics of a travel care clinic. This was conducted in an 18 months period, which consisted of patient recruitment, surgery and follow-up. Ethical permission was received through the Institutional Ethics Committee and informed consent was written in all the participants before the inclusion in the study.

3.2. SAMPLE SIZE AND POPULATION

A total of 96 patients with intertrochanteric fracture of the femur who were of age 60 years and above were selected and had to have the fractures mentioned as verified by radiograph. The sample size was calculated with reference to the old research comparing the PFN and DHS fixation functional outcomes and there was sufficient statistical power.

Patients have been separated into two equal groups:

- Group 1 (DHS group): 48 patients treated with Dynamic Hip Screw fixation
- Group 2 (PFN group): 48 patients treated with Proximal Femoral Nailing

All patients were followed up for a minimum period of 6 months after surgery to assess both functional and radiological outcomes.

3.3. INCLUSION CRITERIA

- Age \geq 60 years
- Intertrochanteric fracture (classified as AO/OTA type A1–A3)
- Patient was able to walk independently before the injury (with or without walking aid)
- Surgery performed within 2 weeks of injury

3.4. EXCLUSION CRITERIA

- Pathological fractures (due to bone tumors or infections)
- Polytrauma or multiple limb injuries
- Old or neglected fractures more than 3 weeks old
- Periprosthetic fractures around previous implants
- Previous hip surgery on the same side
- Patients unfit for anesthesia or surgery

3.5. PREOPERATIVE EVALUATION

All patients underwent:

- Thorough clinical inspection such as evaluation of shortening of limbs, external rotation and tenderness.
- Radiographic analysis of anteroposterior (AP) view of the pelvic torso-pelvis and lateral view of the affected hip.
- Routine blood tests (coagulation, blood sugar, renal, CBC, and bloodsgas).
- Physician and anesthetic physician medical examination.

3.6. SURGICAL PROCEDURE

The physicians used traction table in order to operate the patients under spinal or regional anesthesia.

- In the case of DHS fixation, a proximal femoral proximal approach was adopted. The fracture was minimized under the C-arm-direction and secured with the help of a lag screw and side plate system.
- PFN fixation For PFN fixation a small incision was created around the greater trochanter followed by the insertion of a short intramedullary nail comprising of two proximal screws and one distal locking screw under fluoroscopic guidance.
- All the surgeries were conducted by well-trained orthopaedic surgeons after the normal standards of aseptic precautions.

3.7. POSTOPERATIVE CARE

- 48 hours postoperative antibiotics were administered.
- On the first postoperative day, the exercises and movements of the ankle, as well as that of the quadriceps, were initiated, and were conducted as static exercises.
- Partial weight-bearing: The third to the fifth day was suggested to be used based on the pain and stability of the patient on a walker.
- Full weight-bearing, of course, on radiological evidence of union (which typically took 12-14 weeks).
- Stitches were taken off 12-14 days.

3.8. FOLLOW-UP

All the patients were called 1 month, 3 months, and 6 months after undergoing surgery.

These assessments were done at each visit:

- Gait, range of motion, pain, and walking ability (Clinical examination).
- Functional Examination: with Harris Hip Score (HHS).

- Radiological evaluation: Use of X-rays to ensure that there is no union, and position of the implants, and any complications which could include screw migration or varus collapse.

3.9. OUTCOME MEASURES

1) **Primary Outcome: Functional outcome measured using Harris Hip Score (HHS) at 1, 3 and 6 months.**

2) **Secondary Outcomes:**

- The bone union time (in weeks) measured radiologically.
- Postsurgical problems such as infection, implantation failure, limb shortening or screw cut-out.

3.10. STATISTICAL ANALYSIS

All of these data were recorded in Microsoft Excel and processed by using SPSS software version 25.

- Continuous data were presented as mean \pm standard deviation (SD).
- Categorical data were expressed as percentages and frequencies.
- Independent t-test was used for comparing continuous variables between groups.
- Chi-square test was applied for categorical variables.
- A p-value < 0.05 was considered statistically significant.

Figure 2

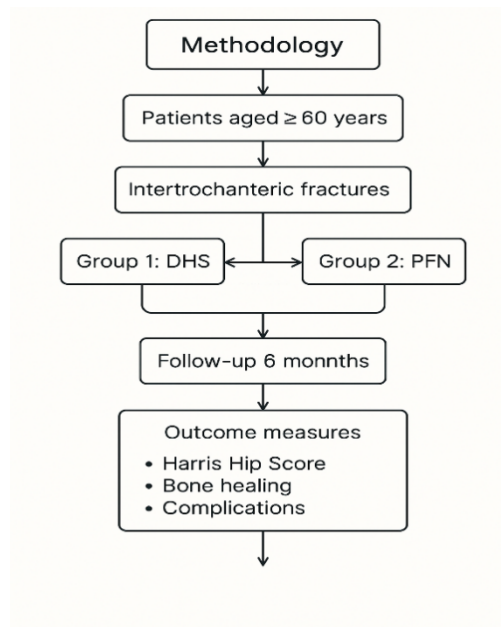


Figure 2 Flowchart showing the methodology of the study — from patient selection to grouping, follow-up, and outcome assessment (HHS, bone healing, and complications).

3.11. ETHICAL CONSIDERATIONS

The IEC gave the study its approval.

- Each participant signed an informed consent.
- Patient data was kept in a confidential manner.
- The research adhered to ethical principles presented in the Declaration of Helsinki (2013 version).

4. RESULTS

In this comparative study, 96 patients who sustained fractures around the intertrochanteric point were used. These included 48 patients all treated using Dynamic Hip Screw (DHS) fixation and 48 patients using Proximal Femoral Nailing (PFN). Follow-ups of all the patients were done over a six-month period after surgery.

4.1. DEMOGRAPHIC PROFILE

- The mean age of the patients was 72yrs with a range of 60 to 88yrs.
- Females (56) and males (40) were 58 and 42 percent respectively, respectively with a minor female bias stemming out of postmenopausal osteoporosis.
- The cause of most fractures was domestic falls whereas there were minor road traffic accidents that caused few fractures.
- 52 patients (54percent) and 44 patients (46percent) involved the right and the left sides respectively.

4.2. FUNCTIONAL OUTCOME

Hip functioning at 1 month, 3 months and 6 months after surgery were assessed using Harris Hip Score (HHS).

Follow-up	DHS (Mean ± SD)	PFN (Mean ± SD)	p-value	Interpretation
1 month	52.1 ± 5.4	58.2 ± 5.0	<0.05	Significant improvement with PFN
3 months	69.5 ± 6.2	74.8 ± 5.8	<0.05	PFN showed faster recovery
6 months	78.9 ± 7.1	85.2 ± 6.4	<0.01	PFN had better long-term function

The mean HHS of the PFN group at the conclusion of 6 months was 85.2, which means good to excellent performance and the DHS group scored 78.9 which means fair to good.

4.3. RADIOLOGICAL OUTCOME

The average bone union time was:

- PFN group: 12 weeks (range 10–14 weeks)
- DHS group: 14 weeks (range 12–16 weeks)

Union was considered complete when there was bridging callus formation in at least three cortices on X-rays and the patient could bear full weight without pain. The difference in union time between both groups was statistically significant ($p < 0.05$), showing faster healing with PFN.

4.4. COMPLICATIONS

Postoperative complications were carefully recorded during follow-up.

1) DHS group:

- 4 patients (8.3%) had screw cut-out due to varus collapse.
- 2 patients (4.1%) developed varus deformity ($>10^\circ$).
- case of superficial infection that healed with antibiotics.

1 PFN group:

- 1 patient (2%) had Z-effect (proximal screw migration).
- 1 patient (2%) had a mild superficial infection.
- No cases of implant breakage or deep infection were noted.

Overall, the PFN group had fewer complications than the DHS group, indicating better stability and reduced implant failure.

4.5. COMPARISON OF FUNCTIONAL GRADES

At the final follow-up (6 months), results were classified based on Harris Hip Score grades.

Functional Grade	Score Range	DHS (n=48)	PFN (n=48)
Excellent	90–100	10 (20.8%)	18 (37.5%)
Good	80–89	22 (45.8%)	24 (50.0%)
Fair	70–79	10 (20.8%)	6 (12.5%)
Poor	<70	6 (12.5%)	0 (0%)

The PFN group achieved a higher number of “excellent” outcomes compared to the DHS group. No patient in the PFN group had a poor outcome.

4.6. HOSPITAL STAY AND MOBILIZATION

1) Average hospital stays:

- DHS: 9.4 ± 2.1 days
- PFN: 7.8 ± 1.8 days

2) Time to partial weight-bearing:

- PFN: within 5–7 days
- DHS: 10–12 days

Patients in the PFN group were mobilized earlier and discharged sooner compared to those treated with DHS.

4.7. SUMMARY OF RESULTS

- 1) The mean age of the study population was 72 years, with a majority being female.
- 2) Harris Hip Scores were consistently higher in the PFN group at all follow-ups.
- 3) Bone healing occurred faster in PFN (average 12 weeks) than in DHS (average 14 weeks).
- 4) Complication rate was lower in PFN (4%) than DHS (12%).
- 5) Functional outcomes were significantly better with PFN, especially in unstable fracture types (A2 and A3).
- 6) Hospital stay and rehabilitation time were shorter in PFN-treated patients.

5. DISCUSSION

Hip fractures in elderly people are common because of weak bones and simple falls (Torretta & Wiesel, 2010). The main aim of treatment is to fix the fracture firmly so that the patient can start walking early and avoid complications of long bed rest.

In this study, two commonly used fixation methods Dynamic Hip Screw (DHS) and Proximal Femoral Nailing (PFN) — were compared in elderly patients with intertrochanteric fractures (Oestern et al., 2014). The findings indicated that PFN has superior general presentations in regard to quicker bone healing, reduced complications and enhanced hip functioning.

Functional Outcome

The Harris Hip Score was more in the PFN group at the three follow-ups (1, 3 and 6 months). This implies that PFN treated patients were in the position to move and walk earlier as compared to the DHS treated patients. Chandy and Saju (2021) and Raviraj et al. (2012) reported comparable results resulting in an improved function and quicker recovery with PFN.

Bone Healing

PFN had an average bone union time of 12 weeks and DHS had a bone union time of 14 weeks. This is due to the fact that the faster union with PFN offers them better stability and less stress on the implant. These findings are consistent with Bali et al. (2013) and Sarma et al. (2016), who discovered previous healing using PFN.

Complications

PFN group was less problematic (4) than the DHS (12). Hampering hole and varus deformity were noticed mostly in DHS cases and PFN experienced one BFN and one mild infection. This demonstrates that PFN is more resilient and secure in the bones with osteoporosis.

Clinical Meaning

PFN enables premature weight bearing, reduced hospitalization and an improved outcome in the long term. DHS is still applicable in cases of stable fracture since it is simple, less expensive and easier to practice.

Limitations

The following had a limited sample size and duration of follow up. It requires more studies with more and longer-term follow-ups.

Conclusion of Discussion

In conclusion, PFN can be identified as a superior choice with unstable intertrochanteric fractures, whereas DHS could be the appropriate choice with stable ones. The photographed findings indicate the application of PFN to elderly patients in order to ensure early mobility and quicker recovery.

6. LIMITATIONS

Despite the fact that the study yielded effective results, there are some limitations which have to be taken into account when interpreting the results:

- 1) The number of patients studied was low (96); thus, it might not be able to represent the bigger population of elderly patients with intertrochanteric fractures.
- 2) The follow-up time was also quite short (six months) thus it was impossible to evaluate long-term effects like fatigue of the implantation, late collapse, or avascular necrosis.
- 3) This could have been impacted by the experience and technique of the surgeon since the different surgeons carried out the surgery.
- 4) This research was held in one hospital only, which cannot be used to generalize the findings to other contexts.
- 5) No randomization, patients were categorized according to the preference of the surgeon that could have resulted in selection bias.

7. CONCLUSION

The hip fracture in the elderly is a significant contributing disability to dependence (Ring, 1990). Surgery is beneficial in early fixation of the neck because it assists in recovery mobility, minimizes complications, and lifestyles. In this comparative analysis concerning Proximal Femoral Nailing (PFN) and Dynamic Hip Screw (DHS) in treating intertrochanteric fractures, both techniques had a satisfactory outcome, however, PFN was more effective in general (Regazzoni, 1985).

The patients who were treated with PFN exhibited:

- Quick energy (average 12 weeks) in the bones.
- Greater Harris Hip Scores with every follow-up.
- Less mechanical complications.
- Premature mobilization and reduction of hospitalization.

This demonstrates that PFN ensures better fixation and biomechanical stability particularly in unstable fracture pattern.

Nevertheless, DHS is still a valid and trusted choice in stable intertrochanteric fracture, because it is not complicated, economically feasible, and needs less surgical skills.

Overall, PFN is the preferred choice on unstable fractures in elderly persons to ensure that early rehabilitation and improved functional recovery are achieved whereas DHS can be utilized in case of the stable fracture and the resources or experience is scarce.

CONFLICT OF INTERESTS

None.

ACKNOWLEDGMENTS

None.

REFERENCES

- Lim, J., Beom, J., & Lee, S. Y. (2018). Osteoporosis and fragility fracture. In Elsevier eBooks (pp. 27–42). <https://doi.org/10.1016/b978-0-323-54454-2.00003-0>
- Mohindra, M., & Jain, J. K. (2017). Fundamentals of Orthopedics. JP Medical Ltd.
- Pignolo, R. J., Keenan, M. A., & Hebel, N. M. (2010). Fractures in the elderly: A Guide to Practical Management. Springer Science & Business Media.
- Sheng, Z., Cheng, X., & Wang, X. (2023). Assessment of osteoporotic fractures and risk prediction. Frontiers Media SA.
- Canale, S. T., & Beaty, J. H. (2012). Campbell's Operative Orthopaedics E-Book: Expert Consult Premium Edition - Enhanced Online Features. Elsevier Health Sciences.
- Regazzoni, P., Rüedi, T., Winkler, R., & Allgöwer, M. (2012). The dynamic hip screw implant system. Springer Science & Business Media.
- Browner, B. D. (1996). The Science and Practice of Intramedullary nailing.
- Tornetta, P., III, & Wiesel, S. W. (2010). Operative techniques in orthopaedic trauma surgery. Lippincott Williams & Wilkins.
- Oestern, H., Trentz, O., & Uranues, S. (2014). Bone and joint injuries: Trauma Surgery III. Springer Science & Business Media.
- Ring, E. F. J. (1990). Current research in osteoporosis and bone mineral measurement: Proceedings of the Second Bath Conference on Osteoporosis and Bone Mineral Measurement, Bath, 25-27 June 1990.
- Regazzoni, P. (1985). The dynamic hip screw implant system. Springer Verlag.
- Hertz, K., & Santy-Tomlinson, J. (2023). Fragility fracture and orthogeriatric nursing: Holistic Care and Management of the fragility fracture and orthogeriatric patient. springer.
- Koya, H., Kumar, K., Upendra, T., Sheik, R., & Kumar, K. S. (2020). functional outcome of comminuted proximal tibial fracture treated by locking plate. *international journal of research -granthaalayah*, 8(11), 227–236. <https://doi.org/10.29121/granthaalayah.v8.i11.2020.2440>